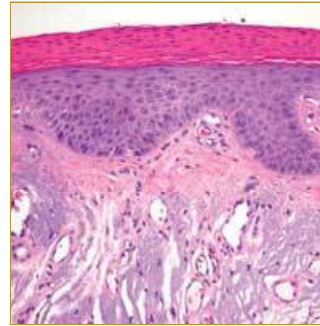
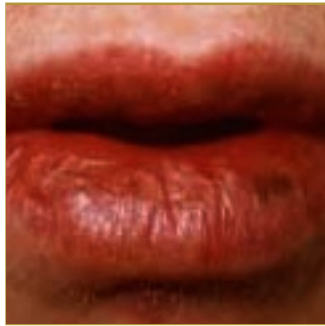



ACTINIC CHEILITIS



EPIDEMIOLOGY: Primarily Caucasian middle-aged men

ETIOLOGY: Excessive exposure to ultraviolet light in teen years and young adult life

PATHOGENESIS: Freckling, loss of elasticity, telangiectasia

CLINICAL: Mild puffiness and vermilion atrophy with admixed blotchy areas of pallor and erythema

HISTOLOGY: Alternating areas of orthokeratosis and parakeratosis. Epidermis might be hyperplastic or atrophic.

ACTINIC CHEILOSI (actinic cheilitis) is a diffuse, degenerative, irreversible alteration of the vermilion border of the lower lip. Occurring primarily in men Actinic Cheilitis does not appear until later on in life. The cause is often extreme sun exposure during young adult life. The lip becomes puffy, blotchy red and pale pink, with occasional white plaques (leukoplakia) and chronic ulcers. The histopathologic characteristics included increased thickness of keratin layer, alterations of the thickness of spinous cell layer, epithelial dysplasia, connective tissue changes, perivascular inflammation and basophilic changes of connective tissue. To prevent further degeneration patients should use lip balm with sunscreens. Occurrence of induration, thickening, ulceration, or leukoplakia should lead to biopsy for histopathologic evaluation. In severe cases without malignancy, a lip shave procedure (vermilionectomy) can remove the vermilion mucosa and replace it with a portion of the intraoral labial mucosa.

BIBLIOGRAPHY

1. "Actinic Cheilosis (Cheilitis)" (Online) <http://www.maxillofacialcenter.com/BondBook/mucosa/actincheilosis.html> (visited: March 13, 2008)
2. Weeden, David AO, MD, FRCPA Skin Pathology, Second Edition Churchill Livingstone 2002.