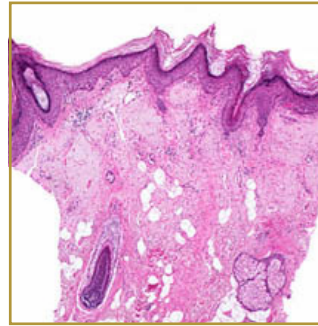
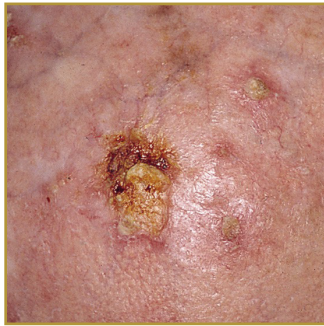




ACTINIC KERATOSIS (AK)



EPIDEMIOLOGY: Occurs primarily in male Caucasians, rate in the United States is estimated to range from 11-26%

ETIOLOGY: Long-term ultraviolet exposure

PATHOGENESIS: Frequency increases with each decade of life. Greater in residents of sunny countries closer to the equator

CLINICAL: Rough spots of skin to elevated, hyperkeratotic plaques several centimeters in diameter

HISTOLOGY: Shares features with squamous cell carcinoma. Aggregates of atypical, pleomorphic keratinocytes at the basal layer that may extend upwards to involve the granular and cornified layers

ACTINIC KERATOSIS (AK) or Solar Keratosis is characterized by dysplasia and architectural disorder of the epidermis. Keratinocytes of the basal layer are abnormal, demonstrating variable sizes and shapes. Cellular polarity is altered, and nuclear atypia is seen. These alterations may extend upward to the granular layer, which may be thinned. Overall, the epidermis exhibits hyperkeratosis and parakeratosis, irregular acanthosis may be present. The lesions normally present themselves in areas of long-term sun exposure. The affected body parts are usually the face, ears, bald scalp in men, and the dorsal forearms and hands. AKs begin as small rough spots that are easier felt than seen. Over time, the lesions grow and become red and scaly. Most are only 3-10 mm, but they may enlarge to several centimeters. The risk of progression to squamous cell carcinoma is minimal, but up to 60% of squamous cell carcinoma cases begin as actinic keratosis. Treatment consists of two broad categories: surgical destruction of the lesion and medical therapy or topical 5-fluorouracil (5-FU), 5% imiquimod cream, topical diclofenac gel, and photodynamic therapy (PDT) with topical delta-aminolevulinic acid.

BIBLIOGRAPHY

1. "Actinic Keratosis" October 2006. (Online) <http://www.emedicine.com/derm/topic9.htm> (visited: March 13, 2008)
2. Weeden, David AO, MD, FRCPA Skin Pathology, Second Edition Churchill Livingstone 2002.