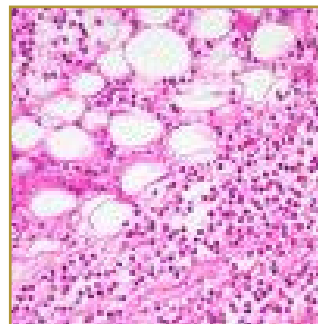
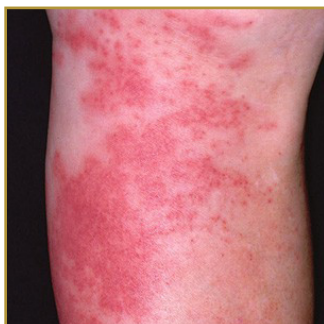



CELLULITIS



EPIDEMIOLOGY: Exact prevalence is uncertain; however, it is a relatively common infection

ETIOLOGY: Organisms on the skin and its appendages gain entrance to the dermis and multiply

PATHOGENESIS: A break in the skin, such as a fissure, cut, laceration, insect bite, or puncture wound

CLINICAL: Involved sites are red, hot, swollen, and tender

HISTOLOGY: Findings of soft tissue inflammation, leukocyte infiltration, capillary dilatation, and bacterial invasion of tissue are observed.

CELLULITIS is an acute infection of skin and soft tissues characterized by localized pain, swelling, tenderness, erythema, and warmth. Cellulitis is unrelated to cellulite, a cosmetic condition featuring dimpling of the skin. Predisposing conditions for cellulitis include insect bite, animal bite, tattoos, pruritic skin rash, recent surgery, athlete's foot, dry skin, eczema, injecting drugs (especially subcutaneous or intramuscular injection or where an attempted IV injection "misses" or blows the vein); plus burns and boils. Good hygiene and good wound care can lower the risk of cellulitis; Changing bandages daily, dressing wounds appropriately. Medical attention should be received for wounds that are deep, dirty or if there is concern about retained foreign bodies. Oral agents with activity against staphylococci and streptococci (eg, dicloxacillin or flucloxacillin, cephalexin, cefuroxime axetil, erythromycin, clindamycin, cotrimoxazole, amoxicillin/clavulanate) are usually effective for treatment of cellulitis in immunocompetent hosts. Elevating limbs with cellulitis can expedite any excess swelling.

BIBLIOGRAPHY

1. "Cellulitis" (Online) October 2006. <http://www.emedicine.com/derm/TOPI464.HTM> (visited: March 14, 2008)