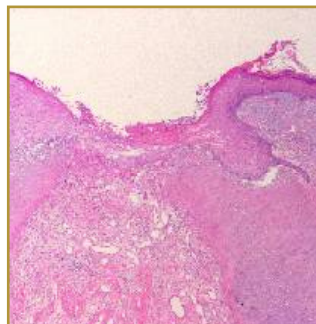
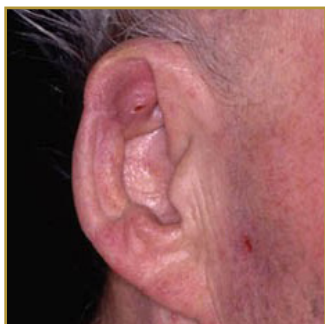



CHONDRODERMATITIS



EPIDEMIOLOGY: Lesions are most often encountered on the helix in white men older than 40 years

ETIOLOGY: Unknown, although most authorities believe it is caused by prolonged and excessive pressure.

PATHOGENESIS: Benign tender lump in the cartilaginous portion of the ear

CLINICAL: Nodules are firm, tender, well demarcated, and round to oval with a raised, rolled edge and central ulcer or crust

HISTOLOGY: Ulceration demonstrates homogeneous acellular collagen degeneration with fibrin deposition

CHONDRODERMATITIS NODULARIS CHRONICA HELICIS (CNH) is a painful inflammatory condition affecting the ear sometimes called Winkler disease. CNH is most often seen in middle-aged or elderly men but may also affect women and younger adults. It results in a benign tender lump in the cartilaginous portion of the ear, the helix. The cause of CNH is not certain; however, it has been linked to pressure, cold, actinic damage, and repeated trauma. The primary goal in treatment is to relieve or eliminate pressure at the site of the lesion, which can often be difficult because of the patient's preference or necessity to sleep on the side of the lesion. Treatments may include topical antibiotics to relieve pain caused by secondary infections, topical and intralesional steroids to relieve discomfort and collagen injections may bring relief by providing cushioning between the skin and cartilage. If specific efforts to relieve pressure are unsuccessful, surgical approaches almost always are needed.

BIBLIOGRAPHY

1. "Chondrodermatitis Nodularis Helicis" (Online) July 2007. <http://www.emedicine.com/derm/TOPIC76.HTM> (visited: March 14, 2008)