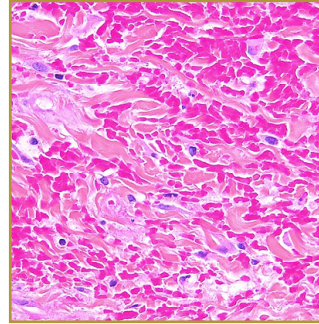
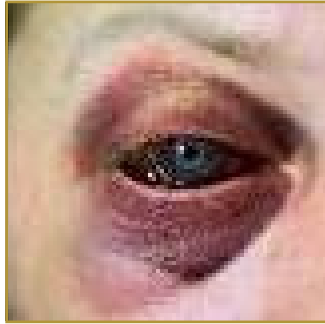



## ECCHYMOSIS



**EPIDEMIOLOGY:** Common

**ETIOLOGY:** Trauma or bleeding/clotting disorder

**PATHOGENESIS:** Blood escapes from the vascular tree and accumulates in the tissues

**CLINICAL:** Hemorrhage into the skin and subcutaneous tissue >1 cm in diameter

**HISTOLOGY:** Presence of red blood cells lying outside of capillaries

**ECCHYMOSIS**, is caused by bleeding under the skin, which occurs from broken blood vessels that form tiny pin-point red dots (called petechiae). Ecchymosis can similarly occur in mucous membranes like in the mouth. Blood also can collect under the tissue in larger flat areas (called purpura), or in a very large bruised area. Aside from the common bruise, bleeding into the skin or mucous membranes is a very significant sign and should always be checked out. Redness of the skin (erythema) should not be mistaken for bleeding; petechiae, purpura, and ecchymosis do not become pale with pressure. Apply ice packs to the injured body area immediately after the injury and apply pressure. The ice pack must be kept on for at least 20 minutes. It may be alternated with a heat pack for the next 48 hours. The bruise will undergo the stages of healing changing colors from red to purple to yellow to brown.

### BIBLIOGRAPHY

1. "Bruise mark treatment" (Online) July 2007. <http://www.umm.edu/ency/article/002039.htm> (visited: March 17, 2008)
2. "Black Eye" (Online). October 2007 [http://www.emedicinehealth.com/black\\_eye/article\\_em.htm102893](http://www.emedicinehealth.com/black_eye/article_em.htm102893) (visited: March 17, 2008)