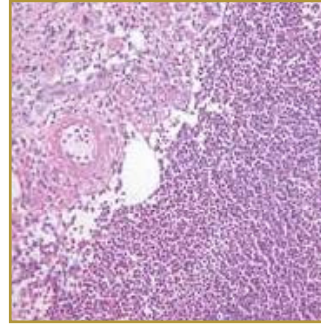
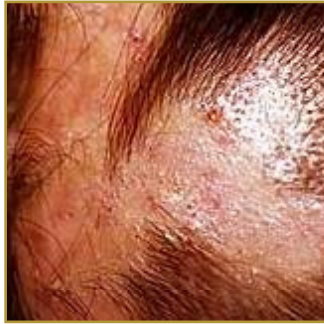



## FOLLICULITIS DECALVANS



**EPIDEMIOLOGY:** Rare

**ETIOLOGY:** Unknown

**PATHOGENESIS:** Hair loss that develops slowly, often over years

**CLINICAL:** Tufts of 8-15 hairs that appear to emerge from a single follicular orifice in a “doll’s hair” pattern

**HISTOLOGY:** Hyperkeratosis, with parakeratosis, overlying a hyperplastic epidermis

**FOLLICULITIS DECALVANS** is a slowly spreading inflammation of the hair follicle, which leads to progressive scarring. It is distinguished by follicular plugging and multiple rounded or oval patches can be found on the scalp, each surrounded by crops of follicular pustules. There may be no other changes, but successive crops of pustules, each followed by the destruction of the affected follicles, produce the slow extension of the alopecia. The exact cause of this condition is unknown, but is most likely an abnormal ‘host response’ to various common bacteria. Patients with this condition report hair loss that develops slowly, often over years with accompanying pain or swelling of the affected scalp. Crust and scales have also been noted in the affected area. Treatments include topical treatments to decrease scaling. Shampoos containing tar derivatives often are used. Oral antistaphylococcal antibiotics may be helpful, particularly if a large amount of purulent exudates is present.

### BIBLIOGRAPHY

1. “Folliculitis Decalvans” (Online) November 2006. [www.dermnet.org.nz/hair-nails-sweat/folliculitis-decalvans.html](http://www.dermnet.org.nz/hair-nails-sweat/folliculitis-decalvans.html) (visited: March 18, 2008)
2. “Tufted Hair Folliculitis” (Online) November 2006. [www.emedicine.com/derm/topic439.htm](http://www.emedicine.com/derm/topic439.htm) (visited: March 18, 2008)