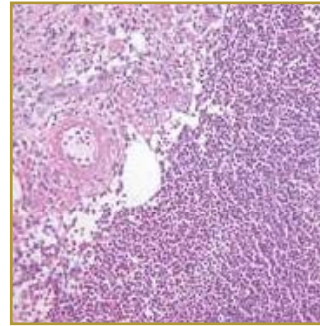
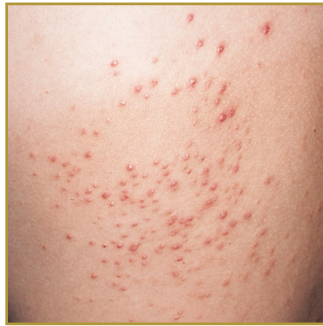



## FOLLICULITIS



**EPIDEMIOLOGY:** Common

**ETIOLOGY:** Primary inflammation of the hair follicle that occurs because of various infections or it can be secondary to follicular trauma or occlusion.

**PATHOGENESIS:** Acute onset of papules and pustules associated with pruritus or mild discomfort

**CLINICAL:** Multiple small papules and pustules on an erythematous base that are pierced by a central hair

**HISTOLOGY:** Moderately intense infiltrate of inflammatory cells in the follicular ostium and upper regions of the follicle

**FOLLICULITIS** is an infection of the hair follicles, in more severe cases permanent hair loss and scarring has been noted. Symptoms and signs of superficial folliculitis include groups of small red bumps that develop around hair follicles; Pus-filled blisters that break open and crust over; Itchiness or tenderness. Deep folliculitis begins deeper in the skin surrounding the hair follicle and affects the entire hair follicle. Symptoms and signs include A large swollen bump or mass; pus-filled blisters that break open and crust over; pain and possible scars once the infection clears. The most common causes of hair follicle damage include Friction from shaving or tight clothing; Excessive perspiration; Inflammatory skin conditions, including dermatitis and acne; Injuries to your skin, such as abrasions or surgical wounds; Covering your skin with plastic dressings or adhesive tape; Exposure to coal tar, pitch or creosote. Topical antibiotics can be used as first-line agents in cases of recurrent superficial folliculitis. If the area infected is a large area or becomes persistent or if an infection has occurred, a health care provider may prescribe systemic antibiotics.

### BIBLIOGRAPHY

1. "Folliculitis" (Online) December 2007. <http://www.emedicine.com/derm/topic159.htm> (visited: March 17, 2008)
2. "Folliculitis" (Online) October 2007. <http://www.mayoclinic.com/health/folliculitis/DS00512/DSECTION=1> (visited: March 17, 2008)