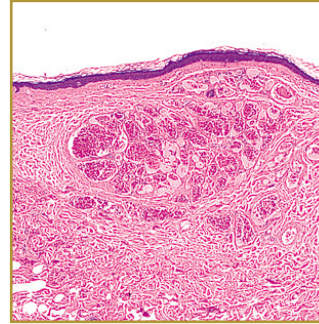
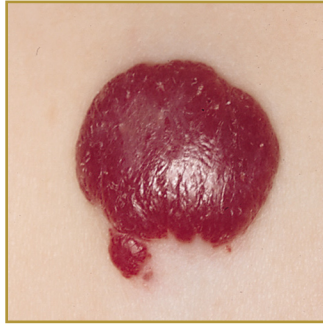




## HEMANGIOMA



**EPIDEMIOLOGY:** Two to three times more common in females, premature babies and Caucasian babies.

**ETIOLOGY:** Some research suggests a link between hemangiomas and certain proteins produced by the placenta during pregnancy.

**PATHOGENESIS:** Usually present at birth, although they may appear within a few months after birth

**CLINICAL:** Starts out as a flat red mark; During the first year of life, the red mark becomes a spongy mass that protrudes from the skin and often grows

**HISTOLOGY:** Show considerable proliferation of their endothelial cells. Cells are large and aggregated in solid strands and masses, only a few small capillaries are observed.

**HEMANGIOMAS** are one of the most common types of birthmarks; they develop when blood vessels group together in one place in the skin. The exact cause of the grouping of blood vessels is not clear, although some research suggests a link between hemangiomas and certain proteins produced by the placenta during pregnancy. Deep and superficial hemangiomas undergo a rapid growth phase increasing the volume and size rapidly. After that phase, very little changes happen, and an involution phase occurs in which the hemangioma begins to disappear, they may disappear completely. Hemangiomas may appear anywhere on the body, they are most disturbing though when they appear on an infant's face or head. If a hemangioma is on they eyelid it may interfere with vision and must be treated in the first few months of life, these are usually treated with injections of steroids or laser treatments that rapidly reduce the size of the lesions, allowing normal vision to develop. On rare occasions, the size and location of hemangiomas may interfere with breathing, feeding, or other vital functions. Superficial or "strawberry" hemangiomas are often not treated. Large cavernous hemangiomas or mixed hemangiomas are treated, when appropriate, with oral steroids and injections of steroids directly into the hemangioma. Recently, lasers have been used to reduce the bulk of the hemangiomas by emitting yellow light which selectively damages the vessels in the hemangioma without damaging the overlying skin.

### BIBLIOGRAPHY

1. "Hemangioma" (Online). October 2006 <http://www.mayoclinic.com/health/hemangioma/DS00848/DSECTION=5> (visited: March 18, 2008)
2. "Hemangioma" (Online). February 2008 <http://www.nlm.nih.gov/medlineplus/ency/article/001459.htm> (visited: March 18, 2008)