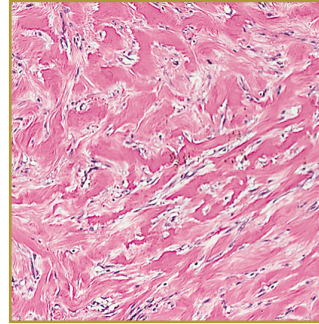
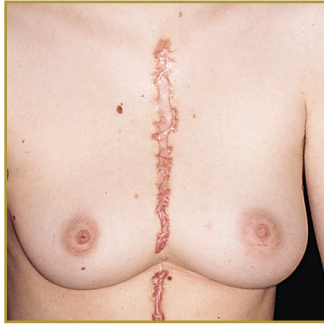



HYPERTROPHIC SCAR



EPIDEMIOLOGY: Individuals of all ethnic backgrounds

ETIOLOGY: Adverse wound healing characteristics, such as infection and excessive wound tension

PATHOGENESIS: Widened or unsightly scar that does not extend beyond the original boundaries of the wound

CLINICAL: Scars are red and thick and may be itchy or painful

HISTOLOGY: Modular structures in which fibroblastic cells, small vessels, and fine, randomly organized collagen fibers are present

HYPERTROPHIC SCAR by definition is a widened or unsightly scar that does not extend beyond the original boundaries of the wound. Keloids and Hypertrophic scars are both associated with adverse wound healing factors and are likely to form in the same location. Unlike keloids, the hypertrophic scar reaches a certain size and then stabilizes or regresses and they do not have a racial or familial preponderance. Hypertrophic scars are common after thermal injuries and other injuries that involve the deep dermis. The scar is usually asymptomatic, but some patients may complain about tenderness, pain, or pruritus. Hypertrophic scars may also cause a burn like feel to the affected area. Cosmetic concern is the main reason patients seek treatment. Treatments may include occlusive dressings, compression therapy, intralesional corticosteroid injections, cryosurgery, excision, radiation therapy, laser therapy, interferon therapy, 5-fluorouracil (5-FU), doxorubicin, bleomycin, verapamil, retinoic acid, imiquimod 5% cream, tamoxifen, tacrolimus, botulinum toxin, and other promising therapies such as transforming growth factor (TGF)-beta3, and recombinant human (rh) interleukin (IL)-10 (rhIL-10), which are directed at decreasing collagen synthesis.

BIBLIOGRAPHY

1. "Hypertrophic Scarring and Keloids" (Online). December 2007 <http://www.emedicine.com/ent/topic37.htm> (visited: March 19, 2008)
2. "Keloid and Hypertrophic Scar" (Online). February 2007. <http://www.emedicine.com/DERM/topic205.htm> (visited: March 19, 2008)