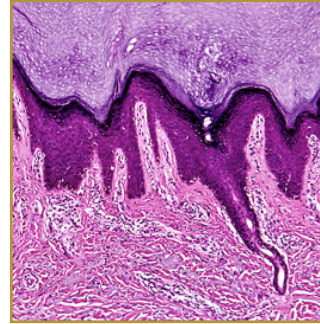
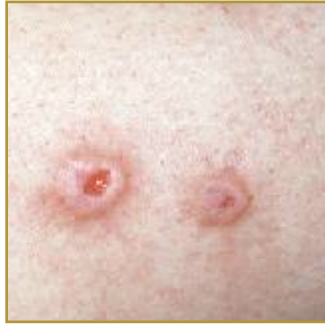



## PRURIGO NODULARIS



**EPIDEMIOLOGY:** Occurs mainly in middle-aged women

**ETIOLOGY:** Unknown; Generally thought to be a form of neurodermatitis

**PATHOGENESIS:** Repetitive scratching causes discrete, nodular, hyperpigmented/purpuric lesions with surfaces that are scaly, excoriated, and possibly crusted

**CLINICAL:** Nodules or papules ranging from 3 – 20 mm in diameter which are scaly, generally symmetric, hyperpigmented or purpuric, and firm

**HISTOLOGY:** Hyperkeratotic epidermis with acanthosis and parakeratosis. Rete ridges are elongated and irregular with a dense dermal infiltrate consisting of neutrophils, eosinophils, histiocytes, and monocytes

**PRURIGO NODULARIS (PN)** is a skin condition that causes sores after repetitive trauma to the skin. Intense pruritus is the main symptom with PN, the individual cannot control the urge to rub or scratch the area, which then results in discrete, nodular, hyperpigmented/purpuric lesions with surfaces that are scaly, excoriated, and possibly crusted. Prurigo nodularis itself is not contagious. The cause is unknown; some factors trigger PN, which include nervous and mental conditions, reduced function of the liver and kidneys, and certain skin diseases such as eczema. Treatments initially will include potent prescription steroid creams, antihistamine creams or pills, anti-depressant pills, and non-prescription Zostrix. In severe cases cryotherapy, oral steroids or PUVA may be recommended.

### BIBLIOGRAPHY

1. "Prurigo Nodularis" (Online). May 2006. <http://www.emedicine.com/derm/topic350.htm> (visited: March 20, 2008)
2. "Prurigo Nodularis" (Online). [http://www.aocd.org/skin/dermatologic\\_diseases/prurigo\\_nodularis.html](http://www.aocd.org/skin/dermatologic_diseases/prurigo_nodularis.html) (visited: March 20, 2008)