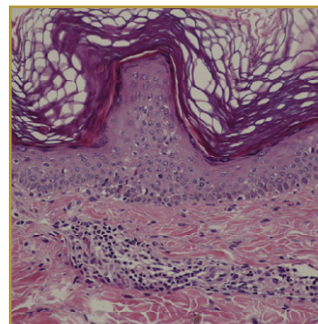
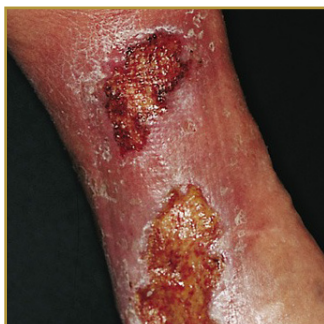



STASIS DERMATITIS



EPIDEMIOLOGY: Approximately 6-7% in patients older than 50 years

ETIOLOGY: Chronic venous insufficiency with venous hypertension

PATHOGENESIS: Swelling is caused when plasma (the fluid portion of blood) leaks out of the blood vessels and into the tissues

CLINICAL: Reddish-brown skin discoloration

HISTOLOGY: Hyperkeratosis, acanthosis, basal pigmentation, and perivascular lymphoid infiltration

STASIS DERMATITIS is a skin condition caused by fluid building up under the skin, due to poor circulation in the veins (venous insufficiency). The poor circulation will eventually lead to ulcers in the skin. Patients typically present with an insidious onset of pruritus affecting one or both lower extremities. Reddish-brown skin discoloration is an early sign of stasis dermatitis and may precede the onset of symptoms. Treatment options available are: Elevating the ankle while resting: Compression therapy (generally accomplished by means of specialized stockings that deliver a controlled gradient of pressure) which must be maintained on a lifelong basis. Compression that is more aggressive can be performed by using elastic wraps or compression boots. Topical therapy: Using wet-to-damp gauze dressings soaked with water or with a drying agent, such as aluminum acetate. Topical corticosteroids are frequently used for reducing inflammation and itching in acute flares.

BIBLIOGRAPHY

1. "Stasis Dermatitis" (Online) November 2005. <http://www.merck.com/mmpe/sec10/ch114/ch114i.html> (visited: March 15, 2008)
2. "Stasis Dermatitis" (Online). February 2007. <http://www.emedicine.com/derm/TOPI403.HTM> (visited: March 15, 2008)