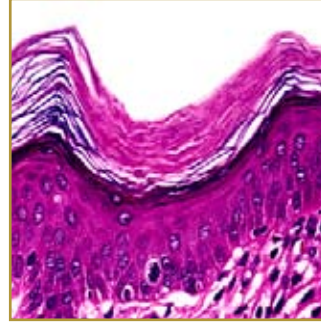
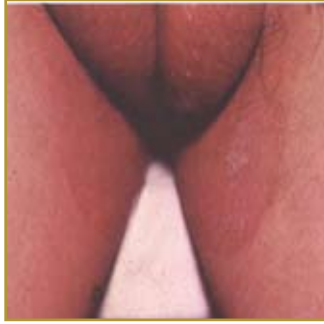

ERYTHRASMA



EPIDEMIOLOGY: Incidence of erythrasma is reported to be around 4% internationally

ETIOLOGY: *Corynebacterium minutissimum*, a member of the normal skin flora, is the causative agent

PATHOGENESIS: Long-term bacterial infection

CLINICAL: Reddish-brown, slightly scaly patches with sharp borders

HISTOLOGY: Diphtheroid bacteria are present in the horny layer as rods and filaments

ERYTHRASMA is a chronic superficial infection of the intertriginous areas of the skin. The incriminated organism is *Corynebacterium minutissimum*, which usually is present as a normal human skin inhabitant. The patches normally are seen in areas with moisture such as the groin, armpit, and skin folds. The infection is found frequently among individuals who are overweight or have diabetes. The rash of erythrasma appears as a slowly enlarging area of pink or brown dry skin that has a fine, scaly, wrinkled surface. Erythrasma is an asymptomatic infection, although sometimes it can feel itchy and uncomfortable. Treatment for the infection include topical antibiotic lotions such as erythromycin or clindamycin; Whitfield's ointment (a mixture of benzoic acid and salicylic acid); Aluminum chloride solution to inhibit sweating and moisture; Oral antibiotics such as erythromycin or clarithromycin.

BIBLIOGRAPHY

1. "Erythrasma" (Online) February 2007. <http://www.emedicine.com/derm/topic140.htm> (visited: March 17, 2008)
2. "Erythrasma" (Online) October 2006. <http://www.nlm.nih.gov/medlineplus/ency/article/001470.htm> (visited: March 17, 2008)