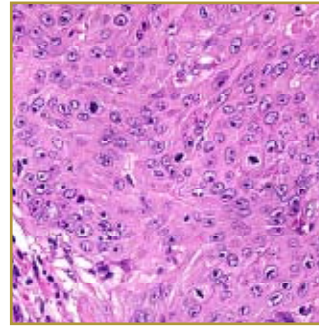
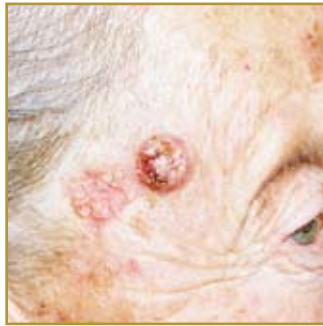

## KERATOACANTHOMA



**EPIDEMIOLOGY:** Most commonly seen in elderly, light-skinned people with a history of sun exposure.

**ETIOLOGY:** Sunlight is an important etiologic factor

**PATHOGENESIS:** Typically grows rapidly, attaining 1-2 cm within weeks, followed by a slow involution period lasting up to 1 year and leaving a residual scar if not excised preemptively

**CLINICAL:** Solitary and begin as firm, roundish, skin-colored or reddish papules that rapidly progress to dome-shaped nodules with a smooth shiny surface and a central crater form ulceration or keratin plug that may project like a horn

**HISTOLOGY:** Singularly well-differentiated squamous epithelium that show only a mild degree of pleomorphism and likely form masses of keratin that constitutes the central core

**KERATOACANTHOMA (KA)** is a rapidly growing skin cancer appearing as a volcano-like bump on sun-exposed skin of middle-aged and elderly individuals. It is considered, by many scientists, that keratoacanthoma is a less serious form of squamous cell carcinoma. Most keratoacanthoma cause only minimal skin destruction, but a few behave more aggressively and can spread to lymph nodes. KA is characterized by rapid growth over a few weeks to months, following this growth in most cases a spontaneous resolution may occur in 4-6 months, leaving a scar in the affected area. Treatment options usually include Cryosurgery (Freezing with liquid nitrogen), Electrodesiccation and curettage (scrape and burn), Removal (excision), Mohs micrographic surgery (tiny slivers of skin are taken from the site) or Radiation treatment. KA is rarely treated with medicine injected directly into the lesion (intralesional chemotherapy). A health-care provider may suggest to patients with multiple lesions to take a pill (isotretinoin) which will reduce their size and number.

### BIBLIOGRAPHY

1. "Keratoacanthoma" (Online). January 2008 <http://www.visualdxhealth.com/adult/keratoacanthoma.htm> (visited: March 20, 2008)
2. "Keratoacanthoma" (Online). March 2007. <http://www.emedicine.com/derm/topic206.htm> (visited: March 20, 2008)