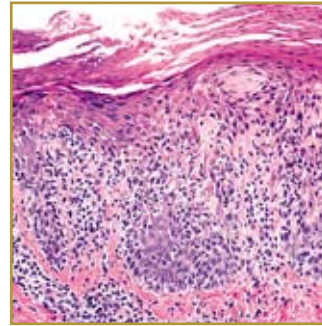
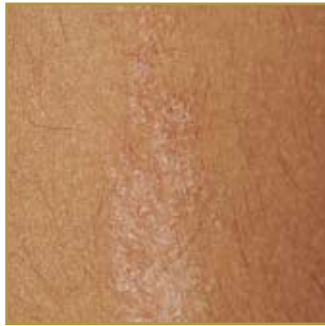

LICHEN STRIATUS



EPIDEMIOLOGY: Occurs more often in children aged 5-15

ETIOLOGY: Unknown; most accepted hypothesis is the combination of genetic predisposition with environmental stimuli

PATHOGENESIS: Small eruption of small papules

CLINICAL: Appears as a linear band consisting of small pink, tan or skin colored papules

HISTOLOGY: Polymorphic epidermal reaction pattern with variable spongiotic and lichenoid changes

LICHEN STRIATUS is a self-limited linear rash appearing often on an extremity. The small papules, which may be smooth, scaly or flat topped are red, tan or the same color of the flesh. Lichen Straitus is usually asymptomatic; the most common complaint with patients is pruritus. The eruption normally grows over a few days to weeks. The cause of Lichen Straitus is unknown but researchers hypothesize that it is a genetic predisposition (atopic dermatitis, asthma, or allergic rhinitis) with environmental stimuli. Lichen Straitus is not contagious. The condition will normally resolve itself around 3 – 12 months, but some medications may be given to patients to treat any associated pruritus or dryness of the skin. Medications include emollients and topical steroids.

BIBLIOGRAPHY

1. "Lichen Striatus" (Online). September 2006. <http://www.emedicine.com/DERM/topic238.htm> (visited: March 24, 2008)
2. "Lichen Striatus" (Online). http://www.aocd.org/skin/dermatologic_diseases/lichen_striatus.html (visited: March 24, 2008)